

Abnormalities of cortical thickness in postictal psychosis

J.M. DuBois^a, O. Devinsky^{a,b}, C. Carlson^a, R. Kuzniecky^a, B.T. Quinn^{a,c}, K. Alper^{a,b}, T. Butler^a, K. Starner^a, E. Halgren^d, T. Thesen^{a,d,*}

^a NYU Comprehensive Epilepsy Center, Department of Neurology, New York University School of Medicine, New York, NY, USA

^b Department of Psychiatry, New York University School of Medicine, New York, NY, USA

^c Center for Neural Science, New York University, New York, NY, USA

^d Multimodal Imaging Laboratory, University of California, San Diego, San Diego, CA, USA

ARTICLE INFO

Article history:

Received 2 February 2011

Revised 15 March 2011

Accepted 19 March 2011

Available online 4 May 2011

Keywords:

Epilepsy

Seizures

Psychosis

Magnetic resonance imaging

Morphometry

ABSTRACT

Postictal psychosis (PIP), the occurrence of psychotic episodes following a seizure, is a common and serious comorbidity in patients with epilepsy. Yet, the anatomical correlates remain poorly defined. Here, we used quantitative MRI morphometry to identify structural abnormalities in the cortex of patients with PIP relative to patients with epilepsy without PIP and age- and gender-matched normal healthy controls. Comparison of patients with epilepsy and PIP with patients with epilepsy without PIP revealed increased cortical thickness in the right lateral prefrontal cortex, right anterior cingulate cortex, and right middle temporal gyrus. The PIP group was distinguished from the EC and NC groups by thicker cortex in the right rostral anterior cingulate cortex and thinner cortex in the right angular gyrus and the left middle temporal region. Findings indicate that PIP is associated with thickening of the right anterior cingulate cortex, which may serve as a marker for patients at risk for developing PIP.

Published by Elsevier Inc.

1. Introduction

Postictal psychosis (PIP) is characterized by psychotic episodes following one or more seizures [1–4], occurs in 6–7% of patients with treatment-resistant epilepsy [5], and accounts for 25–30% of all epilepsy-related psychoses [6,7]. Postictal psychoses usually develop 10 or more years after seizure onset [8]. Episodes of PIP are typically preceded by a cluster of seizures or a recent increase in seizure frequency coupled with changes in mood or behavior [2–4,9]. Symptoms include auditory and visual hallucinations, delusions of grandeur, paranoia, and religiosity [5,10,11]. Psychoses often remit spontaneously after days or weeks, with a mean duration of 70 hours [12]. Recurrent PIP can progress to chronic interictal psychoses (IIPs), suggesting a cumulative effect of repeated seizure activity on brain function and brain structure [13]. In a comprehensive assessment of clinical variables, PIP was associated with ambiguous/extratemporal seizure localization [9].

Findings of structural brain abnormalities in PIP remain inconsistent, however, ranging from diffusely abnormal CT scans [2] to increased frequency of mesial temporal sclerosis [10], larger overall amygdala volume [14], bilateral hippocampal neuron loss at autopsy [15], and higher frequency of temporal lobe dysplasias and preserved ipsilateral anterior hippocampus [16]. Quantitative MRI analysis is sparse and has thus far not distinguished PIP from other forms of

epilepsy-related psychosis. Using voxel-based morphometry, Rüscher et al. [17] found no structural abnormalities in patients with temporal lobe epilepsy and psychosis (i.e., PIP and IIP), whereas another study found that patients with temporal lobe epilepsy and schizophrenia-like IIP had decreased frontoparietal and temporal lobe gray matter volume [18].

To investigate cortical abnormalities specific to postictal psychosis, we compared patients with PIP with diagnostically matched controls with epilepsy and healthy controls, using a measure of cortical thickness that is sensitive to the changes associated with epilepsy [16,19] and other neurological diseases [20,21], including schizophrenia [22,23].

2. Methods

2.1. Participants

Eleven patients with PIP, 11 patients with epilepsy without psychotic features, and 11 healthy controls participated in the study. Patients with PIP were matched with healthy controls for gender, age, and handedness, epilepsy controls for gender, age, handedness, epilepsy type, disease length, and lateralization of seizure foci (see Table 1 for demographic and clinical information). A board-certified neurologist specializing in epilepsy characterized epilepsy features used for matching patient groups. Exclusion criteria for both control groups were any prior or current treatment with antipsychotic medication and any history suspicious of a prior psychotic episode, such as psychiatric

* Corresponding author at: Comprehensive Epilepsy Center, 223 East 34th Street, New York, NY 10016, USA. Fax: +1 917 829 2016.

E-mail address: thomas.thesen@med.nyu.edu (T. Thesen).

Table 1
Demographic and clinical information for patients with postictal psychosis, controls with epilepsy, and healthy controls.

	Patients with postictal psychosis	Controls with epilepsy	Healthy controls
N	11	11	11
Males/females	6/5	6/5	6/5
Age	39.4 (12.9) ^a	39.1 (14.2)	38.1 (13.0)
Handedness (R/L)	11/0	10/1	11/0
Cerebral volume, cm ³	411,789 (29,680.62)	428,655 (53,735.09)	439,060 (45,105.17)
Prior generalized tonic-clonic seizure	7	6	
Disease length	22.4 (11.9)	22.5 (13.1)	
Epilepsy type ^b			
Idiopathic generalized	2	2	
Localization-related	9	9	
Lateralization ^b			
Left	3	4	
Right	3	2	
Bilateral	3	2	
Unknown	0	1	
Seizure frequency			
Daily	2	2	
Weekly	2	3	
Monthly	5	1	
Yearly	1	1	
>Yearly	0	1	
Seizure free	1	3	
Unknown	0	0	

^a Mean (SD).^b Diagnosed on the basis of video/EEG recordings.

hospitalizations or episodes that appeared to possibly involve hallucinations, delusions, or grossly disorganized behavior. All participants consented to the study approved by the NYU Langone School of Medicine institutional review board.

Patients with a history of PIP were recruited retrospectively based on recorded clinical interviews performed by a board-certified psychiatrist (author K.A.). Therefore, not all patients were currently experiencing seizures or psychoses at the time of scanning. Psychosis was diagnosed with DSM-IV-R criteria [24], that is, hallucinations, delusions, or grossly disorganized behavior. Criteria for a diagnosis of PIP were based on Logsdail and Toone [2]: (1) emergence of psychotic state within 7 days of a seizure or seizure cluster; (2) duration of psychotic episode of at least 15 hours; and (3) no evidence of confounding factors that could explain the psychotic state from a clinical cause other than PIP. Table 2 details patients' psychotic and comorbid psychiatric symptoms. Exclusion criteria for PIP included chronic treatment with antipsychotic medication and a diagnosis of pervasive developmental disorder or autism, mental retardation, schizophrenia, schizoaffective, or mood disorder with psychotic features.

2.2. MRI scanning and image preprocessing

Imaging was performed at the NYU Center for Brain Imaging on a Siemens Allegra 3-T scanner. All patients were scanned with a specialized T1-weighted MRI sequence optimized for gray–white matter contrast. Image acquisitions included a conventional three-plane localizer and a T1-weighted volume pulse sequence (TE = 3.25 ms, TR = 2530 ms, TI = 1100 ms, flip angle = 7°, field of view (FOV) = 256 mm, matrix = 256 × 192, voxel size = 1 × 1.33 × 1.33 mm). For each participant, two T1-weighted images were rigid body registered to each other, averaged (to increase signal-to-noise ratio), and reoriented into a common space, roughly similar to alignment based on the anterior commissure–posterior commissure line. Images were corrected for nonlinear warping caused by nonuniform fields created by the gradient coils. Image intensities were further normalized and made uniform with the FreeSurfer (4.0.2) software package.

Table 2
Psychiatric observations in patients with postictal psychosis (PIP).

Isolated episode of PIP	45%
Recurrent episodes of PIP	55%
Postictal delirium	100.00%
Confusion	90.91%
Agitation	45.45%
Fatigue	18.18%
Hallucination	81.82%
Visual	63.64%
Auditory	45.45%
Paranoia	18.18%
Grossly disorganized behavior	27.27%
Hyperreligiosity	9.09%
Other interictal psychiatric diagnoses	
Mood disorder	45.5%
Depression	18.18%
Anxiety	36.36%

Note. Given are the percentages of the total PIP group for the types of postictal and interictal symptoms experienced. Data resulted from a structured psychiatric evaluation performed by a board-certified psychiatrist.

2.3. Surface reconstruction

To quantify the morphological characteristics of the human cerebral cortex, the volumetric MRI scans were used to construct models of each subject's cortical surface using an automated procedure that involves (1) segmentation of the white matter, (2) tessellation of the gray/white matter boundary, (3) inflation of the folded surface tessellation, and (4) automatic correction of topological defects. These steps are described in detail elsewhere [25]. First, an estimate of the gray/white matter boundary was constructed by classifying all white matter voxels in the MRI volume. Then, the white matter surface was refined to obtain submillimeter accuracy in delineating the gray/white matter junction. The surface was then deformed outward to locate the pial surface [26]. Sulcal and gyral features across individual subjects were aligned by morphing each brain to an average spherical representation that allows for accurate matching of cortical locations among participants, while minimizing metric distortion [26].

2.4. Cortical thickness

Cortical thickness was estimated by measuring (1) the shortest distance from each point on the white matter surface to the pial surface, and (2) the shortest distance from each point on the pial surface to the white matter surface. Cortical thickness at each vertex was computed as the average of the two values [26]. Data were then smoothed on the tessellated surface with a gaussian smoothing kernel (FWHM = 15 mm) prior to statistical analysis.

2.5. Statistical analyses

A general linear model was used to compare two-sample contrasts of vertexwise cortical thickness variation. Each contrast (i.e., patients with epilepsy and PIP vs patients with epilepsy only, patients with PIP vs healthy controls, and patients with epilepsy vs healthy controls) then underwent Monte-Carlo cluster analyses to correct for multiple comparisons at a cluster threshold of 0.0500. To differentiate abnormalities specifically associated with PIP, we performed a conjunction analysis of statistically significant clusters in comparisons of patients with PIP versus patients with epilepsy only and patients with PIP versus healthy controls. Only statistically significant regions were combined, thereby conforming to the logical AND test [27,28]. Values for each analysis were then mapped to a partially inflated white matter surface, allowing the optimal visualization of sulcal and gyral features without being obscured by cortical folding.

3. Results

3.1. Cortical thickness

Patients with PIP showed increased cortical thickness in the right lateral prefrontal cortex (PFC), right rostral anterior cingulate cortex (ACC), and right middle temporal gyrus compared with patients with epilepsy without PIP. Smaller and more disperse areas of thickening were found in the left PFC and throughout the left temporal lobe. Compared with healthy controls (HC), patients with epilepsy without PIP (EC) showed widespread cortical thinning maximal in bilateral PFCs, extending to the parietal lobe and including the right middle temporal gyrus and right and left ACC (see Fig. 1A).

To distinguish cortical abnormalities specific to patients with PIP from those related to both the epilepsy and healthy control groups, a conjunction analysis was performed based on PIP group versus EC group and PIP group versus HC group comparisons. This comparison shows only areas where patients with PIP differed significantly from both controls with epilepsy and healthy controls (see Fig. 2). Patients with PIP showed increased thickness in the right rostral ACC and areas of thinning in the right angular gyrus as well as the left anterior inferior temporal gyrus.

4. Discussion

Patients with PIP had thicker cortex in the right lateral PFC, right rostral ACC, and right middle temporal gyrus relative to controls with epilepsy. The right rostral ACC distinguished patients with PIP from both controls with epilepsy and healthy controls. Conjunction analysis additionally revealed two defined regions of thinner cortex in the right angular gyrus and left anterior inferior temporal gyrus.

The approach used here differs from prior PIP studies on two main assumptions. First, although PIP has long been distinguished diag-

nostically from chronic and interictal psychoses of epilepsy [2], many recent quantitative studies have used cohorts of epilepsy-related psychoses that included chronic and interictal psychotic symptoms, despite marked phenomenological and time course differences [13,29]. Second, following initial observation of a greater frequency of temporal lobe epilepsies (TLEs) associated with psychosis [30], many studies focused subsequent analysis specifically on patients with TLE with psychosis compared with controls with TLE. However, in a recent comprehensive analysis of PIP in an unselected group of patients with partial epilepsy, PIP was associated with extratemporal and ambiguous seizure foci [9]. The present study used a homogenous PIP sample and matched control group that allowed the study of PIP without bias for epilepsy type or location of seizure onset. Although cortical abnormalities, especially those revealed by group comparison, are not likely to be fundamentally related to seizure foci, the extratemporal abnormalities observed here, combined with a greater tendency for extratemporal and ambiguous seizure onset, implicate a broader network of neuroanatomical abnormalities underlying PIP than has been acknowledged previously.

Patients with PIP, as compared epilepsy controls and healthy controls, had a thicker rostral ACC. Cognitively, the ACC is associated with attention, inhibitory control, and emotional processing [31–33]. Given the broad functional involvement of these processes, structural abnormalities of the ACC are associated with a multiplicity of disorders, including depression, bipolar disorder, autism, affective psychosis, and schizophrenia [22,34–38]. Consistent with previous observations, mood disorders, depression, and anxiety were common in our PIP sample [5]. A family history of such psychiatric disorders is also a predictor of developing PIP [9]. Counter to our results, however, disorders of mood and psychosis are often associated with decreased thickness of the ACC [22,23,34,36].

Why is the cortex preserved or thickened in epilepsy-related psychosis while it is often found to be thinner in other psychiatric disorders? Despite

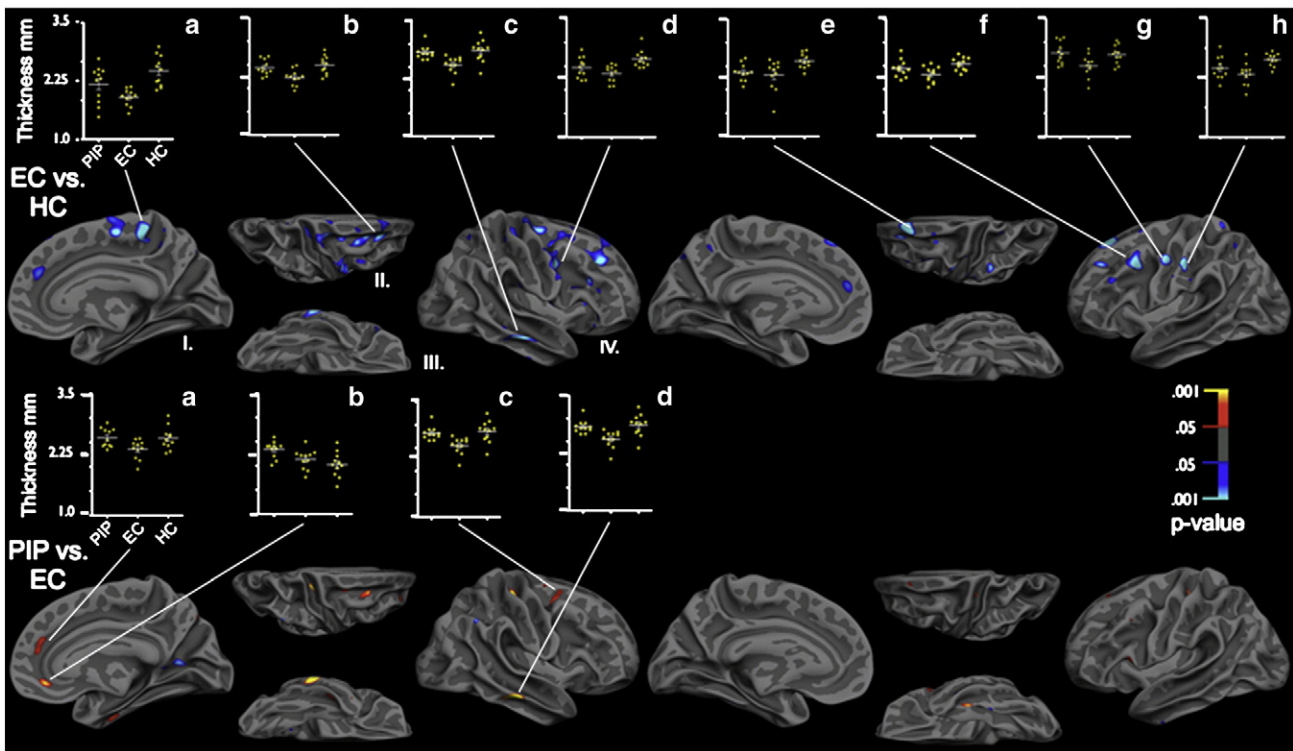


Fig. 1. Cortical thickness differences between groups. Controls with epilepsy (EC) had thinner cortex (as indicated by blue) than healthy controls (HC). Patients with postictal psychosis (PIP) had thicker cortex (red/yellow) compared with EC. Thickness measurements are displayed on the partially inflated white matter surface, in the medial (I), dorsal (II), rostral (III), and lateral (IV) planes. Scatterplots display average thickness for all vertices within specific significant regions of interest ($P < 0.01$) for all groups (PIP, EC, and NC). Average cortical thickness within the specified regions of interest ranged from 1 to 3.5 mm.

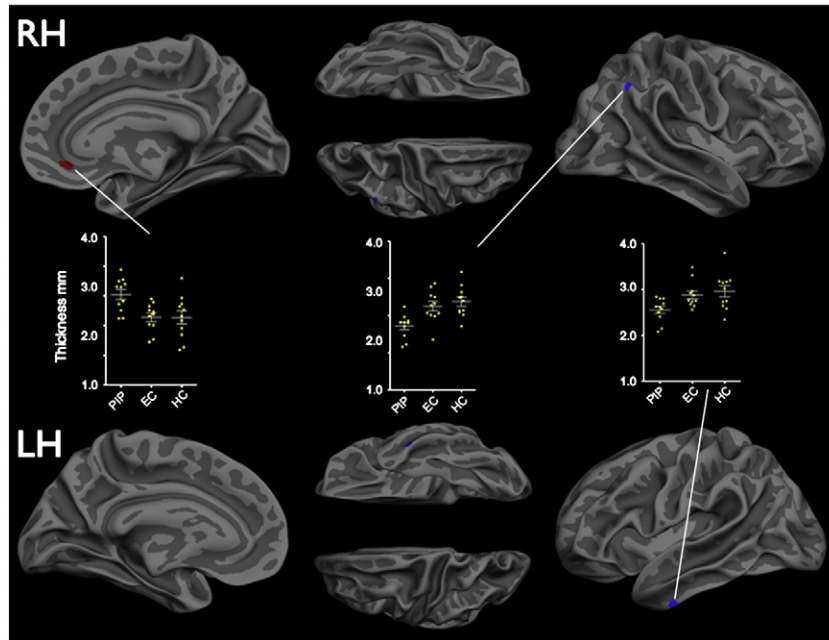


Fig. 2. Conjunction analysis. Shown are overlapping regions of significant ($P < 0.025$) differences in cortical thickness in PIP versus EC and PIP versus HC. Red indicates thickening in patients with PIP, whereas blue indicates thinning. Scatterplots display average thickness for all vertices within the specified cluster for all groups (PIP, EC, and HC). Average cortical thickness within the specified regions of interest ranged from 1 to 4 mm.

divergent structural changes, thicker cortex in patients with PIP may reflect an abnormality functionally similar to thinner cortex in schizophrenia and bipolar disorder. That is, thickening in the ACC of patients with PIP may be due to epileptogenic mechanisms resulting in functionally aberrant cortical networks, which may share commonalities with degraded regions in other psychotic disorders. Candidate mechanisms for enlargement/thickening in postictal psychosis are neuronal hyperactivity [39], inflammatory reactions [40], and focal cortical dysplasia, the neuroimaging features of which include cortical thickening [41]. Future investigations of such conjecture would require a larger sample of patients with PIP and direct comparison with other forms of psychosis. Additional studies using surgical specimens or MR spectroscopy would be able to confirm and further characterize findings of focal thickening in PIP, and determine whether thickening results from some combination of increased neuronal or glia size, number, and other factors.

The neuroanatomical features of psychosis in epilepsy remain poorly understood despite its high morbidity and mortality and intensive psychiatric investigations. Our findings of cortical thickening in specific anatomic regions in patients with PIP may help to focus attention on these structures and their role in abnormal behavior. Future studies with larger patient samples that examine structural, metabolic, and neurochemical markers in these regions may further define the underlying pathology of postictal psychosis.

Acknowledgments

Supported by faces (Finding a Cure for Epilepsy and Seizures) (T.T.) and NIH grants NS18741 (E.H.), NS44623 (E.H.)

References

- [1] Devinsky O, Abramson H, Alper K, et al. Postictal psychosis: a case control series of 20 patients and 150 controls. *Epilepsy Res* 1995;20:247–53.
- [2] Logsdail S, Toone B. Post-ictal psychoses: a clinical and phenomenological description. *Br J Psychiatry* 1988;152:246–52.
- [3] Sachdev P. Schizophrenia-like psychosis and epilepsy: the status of the association. *Am J Psychiatry* 1998;155:325–36.
- [4] Umbricht D, Degreef G, Barr W, Lieberman J, Pollack S, Schaul N. Postictal and chronic psychoses in patients with temporal lobe epilepsy. *Am J Psychiatry* 1995;152:224–31.
- [5] Alper K, Devinsky O, Westbrook L, et al. Premorbid psychiatric risk factors for postictal psychosis. *J Neuropsychiatry Clin Neurosci* 2001;13:492–9.
- [6] Dongier S. Statistical study of clinical and electroencephalographic manifestations of 536 psychotic episodes occurring in 516 epileptics between clinical seizures. *Epilepsia* 1959;1:117–42.
- [7] Schmitz B, Wolf P. Psychoses in epilepsy. In: Devinsky O, Theodore WH, editors. *Epilepsy and behaviour*. 3rd ed. revd. *Frontiers of clinical neuroscience*, vol. 12. New York: Wiley; 1991:97–128.
- [8] Kanner AM, Stagno S, Kotagal P, Morris HH. Postictal psychiatric events during prolonged video-electroencephalographic monitoring studies. *Arch Neurol* 1996;53:258–63.
- [9] Alper K, Kuzniecky R, Carlson C, et al. Postictal psychosis in partial epilepsy: a case-control study. *Ann Neurol* 2008;63:602–10.
- [10] Devinsky O. Postictal psychosis: common, dangerous, and treatable. *Epilepsy Curr* 2008;8:31–4.
- [11] Barczak P, Edmunds E, Betts T. Hypomania following complex partial seizures. *Br J Psychiatry* 1988;152:137–9 12.
- [12] Kanemoto K, Kawasaki J, Kawai I. Postictal psychosis: a comparison with acute interictal and chronic psychoses. *Epilepsia* 1996;37:551–6.
- [13] Tarulli A, Devinsky O, Alper K. Progression of postictal to interictal psychosis. *Epilepsia* 2001;42:1468–71.
- [14] Tebartz van Elst L, Baeumer D, Lemieux L, et al. Amygdala pathology in psychosis of epilepsy: a magnetic resonance imaging study in patients with temporal lobe epilepsy. *Brain* 2002;125:140–9.
- [15] Mathern GW, Pretorius JK, Babb TL, Quinn B. Unilateral hippocampal mossy fiber sprouting and bilateral asymmetric neuron loss with episodic postictal psychosis. *J Neurosurg* 1995;82:228–33.
- [16] Briellmann RS, Kalnins RM, Hopwood MJ, Ward C, Berkovic SF, Jackson GD. TLE patients with postictal psychosis: mesial dysplasia and anterior hippocampal preservation. *Neurology* 2001;55:1027–30.
- [17] Rüsçh N, Tebartz van Elst L, Baeumer D, Ebert D, Trimble MR. Absence of cortical gray matter abnormalities in psychosis of epilepsy: a voxel-based MRI study in patients with temporal lobe epilepsy. *J Neuropsychiatry Clin Neurosci* 2004;16:148–55.
- [18] Marsh L, Sullivan EV, Morrell M, Lim KO, Pfefferbaum A. Structural brain abnormalities in patients with schizophrenia, epilepsy, and epilepsy with chronic interictal psychosis. *Psychiatry Res Neuroimaging* 2001;108:1–15.
- [19] McDonald CR, Hagler DJ, Ahmadi ME, et al. Regional neocortical thinning in mesial temporal lobe epilepsy. *Epilepsia* 2008;49:794–803.
- [20] Rosas HD, Liu AK, Hersch S, et al. Regional and progressive thinning of the cortical ribbon in Huntington's disease. *Neurology* 2002;58:695–701.
- [21] Sailer M, Fischl B, Salat D, et al. Focal thinning of the cerebral cortex in multiple sclerosis. *Brain* 2003;126:1734–44.
- [22] Kuperberg GR, Broome MR, McGuire PK, et al. Regionally localized thinning of the cerebral cortex in schizophrenia. *Arch Gen Psychiatry* 2003;60:878–88.

- [23] Narr KI, Bilder RM, Toga AW, et al. Mapping cortical thickness and gray matter concentration in first episode schizophrenia. *Cerebral Cortex* 2005;15:708–19.
- [24] Diagnostic and statistical manual of mental disorders. 4th ed. Washington, DC: American Psychiatric Assoc.; 1994.
- [25] Dale AM, Fischl B, Sereno MI. Cortical surface-based analysis: I. Segmentation and surface reconstruction. *NeuroImage* 1999;9:179–94.
- [26] Fischl B, Dale AM. Measuring the thickness of the human cerebral cortex from magnetic resonance images. *Proc Natl Acad Sci USA* 2000;97:11050–5.
- [27] Friston K, Holmes A, Price C, Büchel C, Worsley K. Multisubject fMRI studies and conjunction analyses. *NeuroImage* 1999;10:385–96.
- [28] Nichols T, Brett M, Andersson J, Wager T, Poline JB. Valid conjunction inference with the minimum statistic. *NeuroImage* 2005;25:653–60.
- [29] Elliott B, Joyce J, Shorvon S. Delusions, illusions and hallucinations in epilepsy: 2. Complex phenomena and psychosis. *Epilepsy Res* 2009;85:172–86.
- [30] Slater E, Beard AW. The schizophrenia-like psychoses of epilepsy: i. Psychiatric aspects. *Br J Psychiatry* 1963;109:95–112.
- [31] Botvinick MM, Cohen JD, Carter CS. Conflict monitoring and anterior cingulate cortex: an update. *Trends Cogn Sci* 2004;8:539–46.
- [32] Devinsky O, Morrell MJ, Vogt BA. Contributions of anterior cingulate cortex to behaviour. *Brain* 1995;8:304–6.
- [33] Bush G, Luu P, Posner MI. Cognitive and emotional influences in anterior cingulate cortex. *Trends Cogn Sci* 2000;4:215–22.
- [34] Cotter D, Mackay D, Landau S, Kerwin R, Everall I. Reduced glial cell density and neuronal size in the anterior cingulate cortex in major depressive disorder. *Arch Gen Psychiatry* 2001;58:545–53.
- [35] Drevets WC, Price JL, Simpson JR, et al. Subgenual prefrontal cortex abnormalities in mood disorders. *Nature* 1997;6627:824–6.
- [36] Ellison-Wright I, Bullmore E. Anatomy of bipolar disorder and schizophrenia: a meta-analysis. *Schizophrenia Res* 2010;117:1–12.
- [37] Chan AS, Han YMY, Leung WW, Leung C, Wong VCN, Cheung M. Abnormalities in the anterior cingulate cortex associated with attentional and inhibitory control deficits: a neurophysiological study on children with autism spectrum disorders. *Res Autism Spectrum Disord* 2011;5:254–66.
- [38] Koo MS, Levitt JJ, Salisbury DF, Nakamura M, Shenton ME, McCarley RW. A cross-sectional and longitudinal magnetic resonance imaging study of cingulate gyrus gray matter volume abnormalities in first-episode schizophrenia and first-episode affective psychosis. *Arch Gen Psychiatry* 2008;65:746–60.
- [39] Sokol DK, Demyer WE, Edwards-Brown M, Sanders S, Garg B. From swelling to sclerosis: acute change in mesial hippocampus after prolonged febrile seizure. *Seizure* 2003;12:237–40.
- [40] Vezzani A, Moneta D, Richichi C, et al. Functional role of inflammatory cytokines and antinflammatory molecules in seizures and epileptogenesis. *Epilepsia* 2002;43(Suppl 5):30–5.
- [41] Kuzniecky RI, Barkovich AJ. Malformations of cortical development and epilepsy. *Brain Dev* 2001;23:2–11.